

Use of comfeel Plus in the treatment of a debrided traumatic wound.

Petra Quintens: Independent home care nurse, Belgium

Introduction

Traumatic wound that was treated by the patient herself, became a necrotic stagnating wound.

After mechanical debridement (doctor) the wound was assessed with the Triangle of Wound assessment and treated as an acute clean wound.

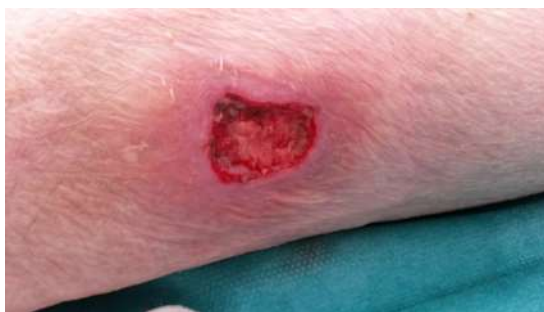Patient



71 year old female, COPD , often treated with corticosteroids.
Non smoker, still mobile,
Patient bumped into a chair and this caused a wound at her leg. She decided to treat the wound by herself, this caused necrotic tissue and stagnation of the wound healing.
Her doctor did a mechanical debridement that resulted in a red acute wound.

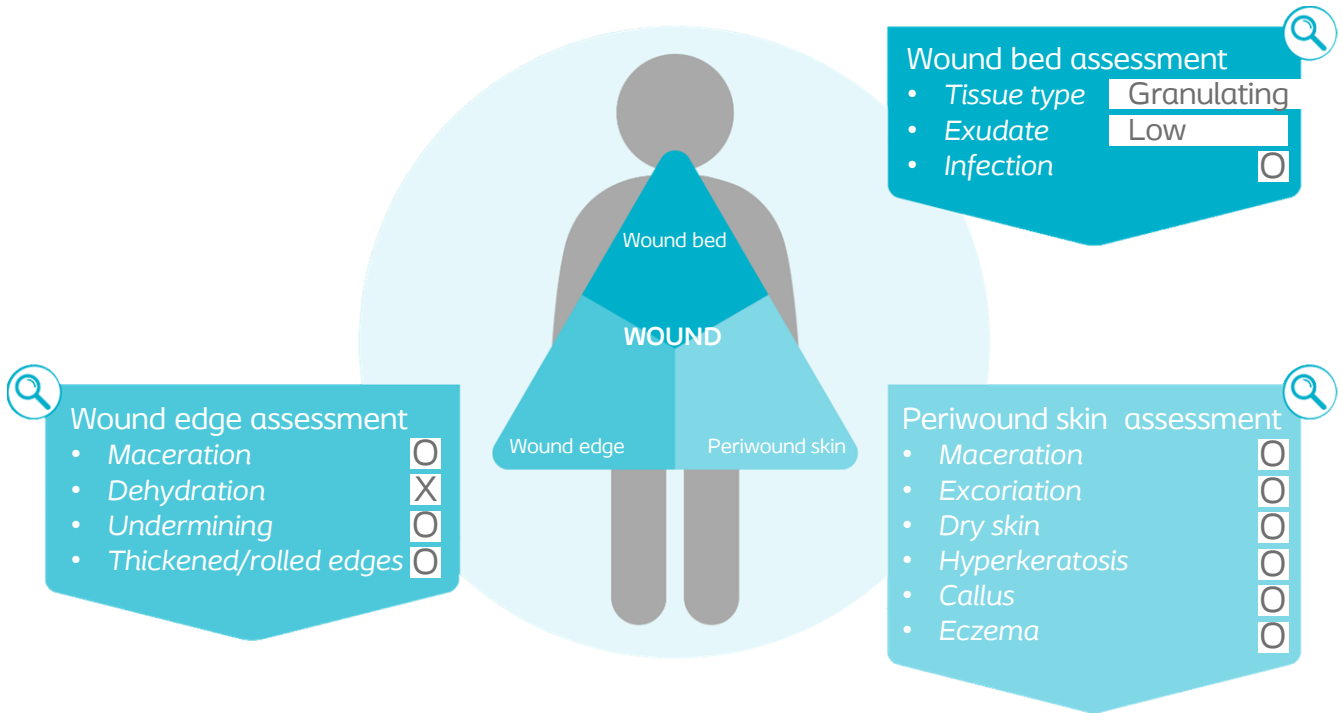


Initial wound assessment



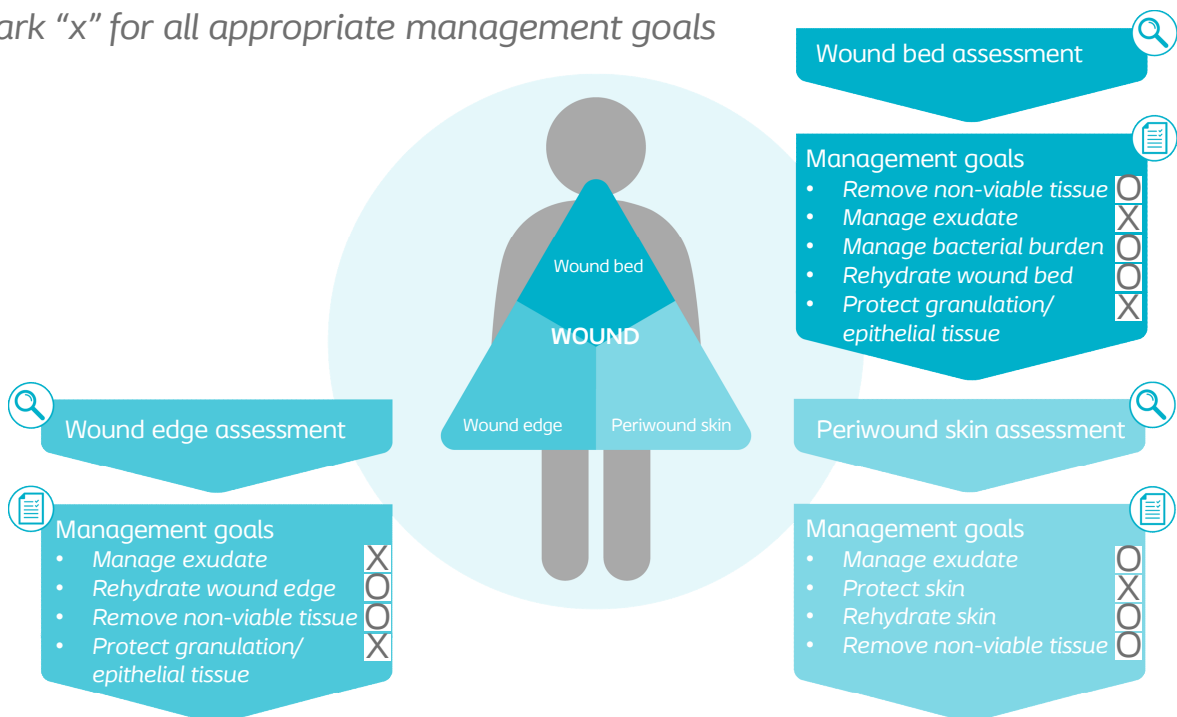
Size of wound	Length	25	mm
	Width	15	mm
	Depth	5	mm

For tissue type and exudate, write findings
 For others, mark "x" for positive findings from assessment,
 and mark "0" if not present



Management goals

Mark "x" for all appropriate management goals



Treatment

Before : patient tried to treat the wound herself with flaminol hydro, resulted in a necrotic wound. Doctor debrided mechanically resulted in a red granulating acute wound.

Treated with : Brava Barrier Spray at the wound edges, Comfeel Plus (17 days) at the wound.

Compression therapy due to venous insufficiency.

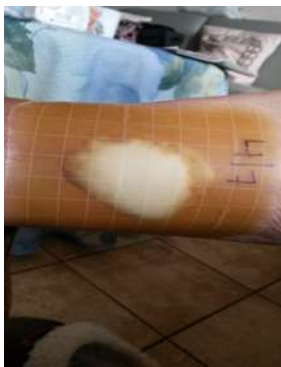Comfeel Plus was changed every 3 days, at the end when exudate level decreased, used Comfeel Plus Transparant with Brava Spray (Last 10 days)

Results

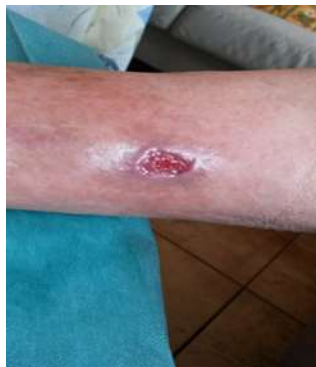Very good result with treatment.

30 days : 20 days use of Comfeel Plus, 10 days use of Comfeel plus Transparant combined with Brava Skin barrier Spray (edge protection)

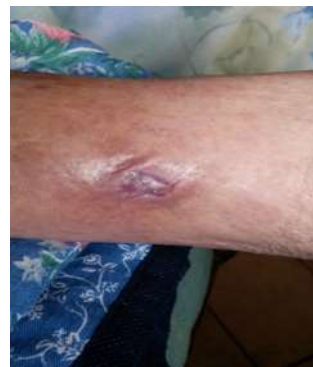Wound healed progressively, and became smaller. Patient didn't feel much pain after a few days with comfeel.



Day 7



Day 22

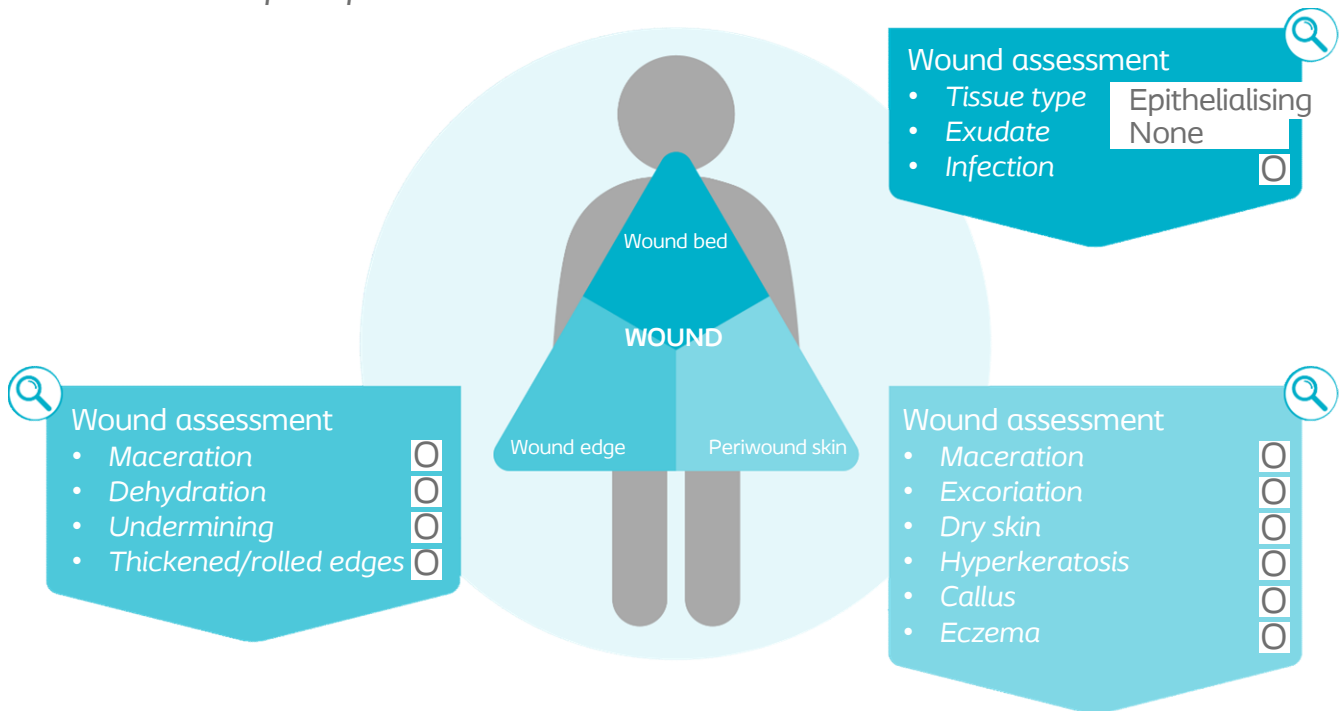


Day 30

Reassessment of the wound at the end of case period

For tissue type and exudate, write findings

For others, mark "x" for findings from assessment, and mark "0" if not present



Conclusion

The wound is fully healed.

Comfeel plus made is possible to treat the wound without disturbing the granulating tissue; The wound edges and peri wound skin were protected by Comfeel Plus.

Comfeel plus was sufficient to cope with the exudate of this wound.

Patient felt protected and comfortable.